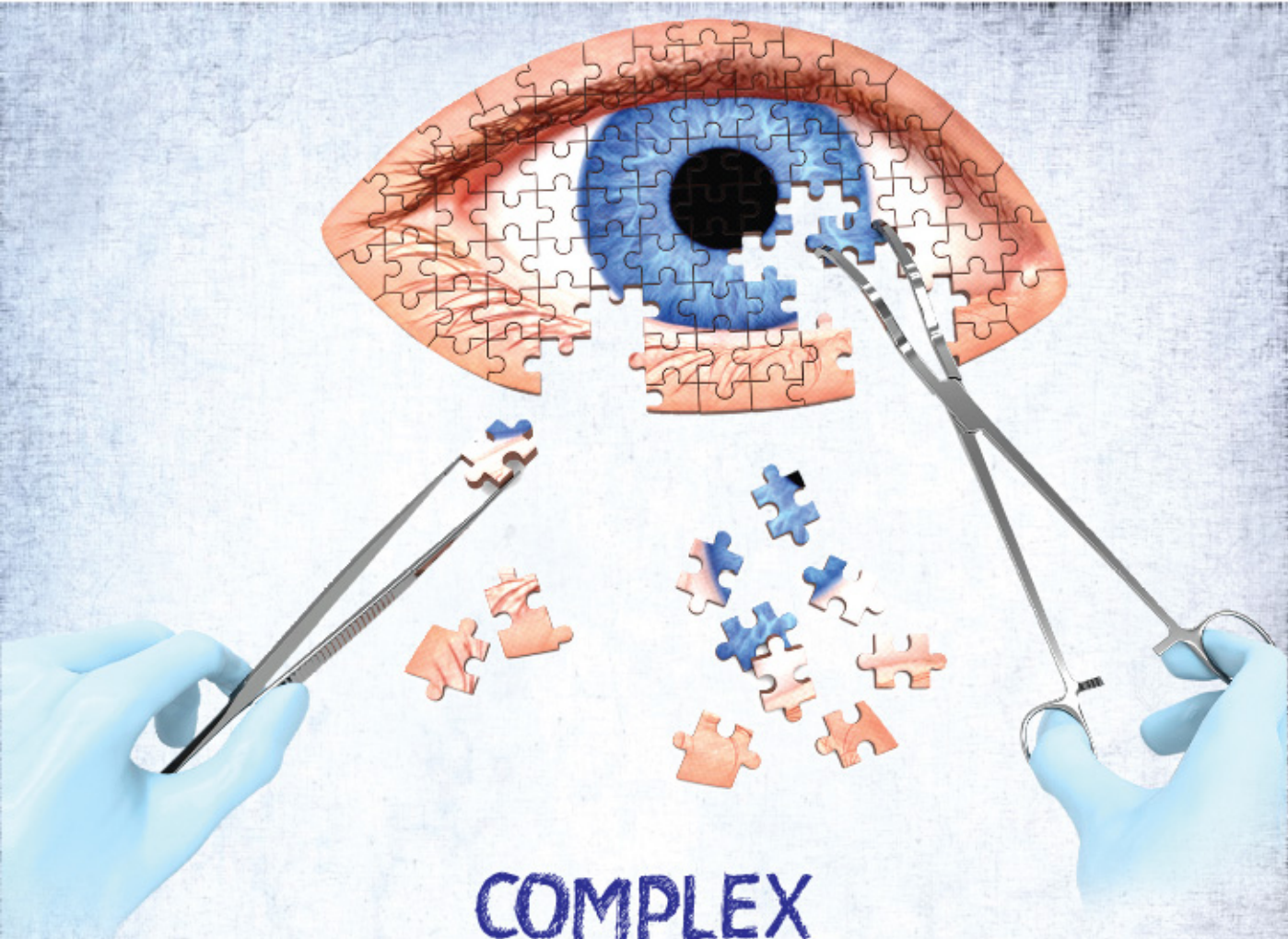



COMPLEX CATARACT & REFRACTIVE SURGERY CLINIX

**20th 21st May 2017
Vivanta By Taj Yeshwantpur, Bangalore**

PROGRAM SCHEDULE

4 CME Credit Hours awarded by Karnataka Medical Council

Under the aegis of Karnataka Ophthalmic Society & Bangalore Ophthalmic Society

DAY 1

SESSION - 1 (09:00 am - 09:30 am)

Glaucoma

Moderators: Dr R Venkatesh, Dr Sathi Devi

CASE
SCENARIO
1

A 52 year old male came with complaints of sudden pain, redness and diminution of vision since last 2 days in the right eye. With circumcorneal congestion, corneal edema and a shallow anterior chamber on examination, an intumescent mature cataract was diagnosed. Intraocular pressure was 42 mm Hg:

15 Min

Raised IOP: When do I take the patient up for surgery?

Dr Harsha Rao

07 Min

Phaco in white intumescent and morgagnian cataract

Dr Harshul Tak

08 Min

CASE
SCENARIO
2

A 60 year old female, on timolol and latanoprost eyedrops in both eyes, IOP of 18 and 15 mm Hg in the right and left eye respectively open angles on gonioscopy in both eyes. Right eye: Nuclear Sclerosis Grade 3 with a cup disc ratio of 0.8 with inferior rim thinning and RNFL defect, Left eye: Nuclear Sclerosis Grade I and a cup disc ratio of 0.7 with inferior rim thinning:

15 Min

Cataract surgery vs Combined Cataract surgery with Trabeculectomy: What's my take?

Dr R Venkatesh

07 Min

Red flags to look for before, during and after surgery

Dr Sathi Devi

08 Min

SESSION - 2 (09:30 am - 11:15 am)

Biometry

Moderators: Dr Harshul Tak, Dr Samaresh Srivastava

CASE
SCENARIO
1

A 55 year old female, a software engineer by profession, with a history of undergoing Radial Keratotomy, has come for cataract surgery in the same eye with an axial length = 29.3 mm

30 Min

How do I optimize the biometry?

Dr. Arulmozhi Varman

07 Min

How can I be sure of visual outcome and what role does aberrometry and topography play?

Dr. Samaresh Srivastava

08 Min

What intraoperative precautions will I take and what parameters do I choose for phacoemulsification?

Dr. Chandrashekar Wavikar

08 Min

Comparison of different biometers

Dr. Mukesh Paryani

07 Min

master  CLASS

Master class (10:00 am - 10:20 am)

My most difficult biometry cases

Dr Fam Han Bor

15 Min

CASE SCENARIO 2 A 45 year old male, a known diabetic with advanced proliferative diabetic retinopathy, with status post pars plana vitrectomy and silicone oil insertion in the right eye, has now come with a mature cataract in the same eye: **15 Min**

How do I calculate the IOL power in this case, and which lens to use? Dr Ashwin Shetty 08 Min

What technical challenges can I expect and how best to manage them during surgery? Dr J K Reddy 07 Min

CASE SCENARIO 3 A 45 year old male with advanced keratoconus, has an immature cataract with nuclear sclerosis Grade 3: **10 Min**

What should I tackle first: Cataract or Cornea? Dr. Rishi Swarup 05 Min

Role of Premium IOLs in Keratoconus Dr Ramesh Dorairajan 05 Min

CASE SCENARIO 4 A 2 year old child with bilateral congenital cataract : **20 Min**

How do I calculate the IOL power and the target refraction? Dr Vaishali Vasavada 08 Min

Rhexis management - Anterior and Posterior Dr Jyoti Matalia 07 Min

When to implant an IOL and where should I place it? Dr Vaishali Vasavada 05 Min

Discussion: 10 minutes

Tea Break 11:15am -11:30 am



Master class (11:30 am - 11:45 am)
Advances in Refractive Surgery:
What does the future hold for us? Dr Ronald Krueger 15 Min

Debate on ICL (11.45am - 01.00 pm) Moderators: Dr J K Reddy, Dr Chandrashekhar Wavikar

A 23 year old female, with -8 D Sph and -2D Cyl in the right eye with ACD = 3mm, white to white = 12 mm and thinnest pachymetry of 490 microns:

a. IPCL Vs ICL Dr Keya Barman Vs Dr Himanshu Matalia 20 Min

b. STS or WTW: What to rely on for sizing? Which WTW to choose? Dr Vaitheeswaran L G 05 Min

c. ICL in keratoconus and pediatric cases. Dr Hemamalini 05 Min

d. Interesting case presentations 20 Min

Lunch 12:45pm -1:30 pm

SESSION - 3 (01:30 pm - 02:15 pm)
Challenges in Cataract Surgery

Moderators: Dr R Krishnaprasad, Dr Y L Rajashekhar

CASE
SCENARIO
1

A 22 year old male patient with hyperextensible joints, and an increased arm span, presented with unicoular diplopia and fluctuating vision. On examination, a grossly subluxated lens was diagnosed:

20 Min

When do I operate this case?

In the Bag vs Scleral Fixated IOL: How do I manage zonular weakness?

Dr Adrian Braganza

10 Min

Femtosecond Laser Assisted Cataract Surgery (FLACS) :
When and how can it help in such a case?

Dr Chee Soon Phaik

10 Min

CASE
SCENARIO
2

A 60 year old hypertensive male with hard brown cataract, non-dilating pupil and no PXF: How will I approach this case?

Dr Harshul Tak

10 Min

master  CLASS

How do I maintain my cool, when the patient is unhappy and distressed?

Dr. K Bhujang Shetty

15 Min

How do I negotiate, buy and get return on investment?

Dr. Y L Rajashekhar

15 Min

Discussion: 15 Minutes

Tea Break (3:15 pm - 3:30 pm)

YOU Session : Video Based Learning (3:30 pm – 6:00 pm)

Mentors: Dr Ronald Krueger, Dr Chee Soon Phaik, Dr Fam Han Bor

Moderators: Dr Deepthi Meda, Dr Praveen Murthy,
Dr Sharon D' Souza, Dr Varun Kharbanda



Keratoconus Screening in Refractive Surgery

Dr Ronald Krueger

15 Min

Step by Step Surgical Video Presentations by Fellows/ Residents / Young Ophthalmologists

Incision and its complications | Capsulorhexis : How to manage extension |
Use of OVDs | Nucleotomy Techniques | PCR management | IOL Yoga | Wound Burns |
Topoguided Treatment Planning | Refractive Sx & SMILE challenges | Lost Flap | Intra Op OCT

**For videos ; 2 Min video followed by 5 Min discussion*

DAY 2

SESSION - 1 (09:00 am - 09:45 am)
Management of unhappy patients

Moderators: Dr Harshul Tak, Dr Chitra Ramamurthy
Dr Krishnaprasad Kudlu

CASE
SCENARIO
1

Post refractive procedures

15 Min

Post refractive dry eye

Dr Rohit Shetty

CASE
SCENARIO
2

Post cataract surgery

15 Min

Interesting case scenarios

Discussants: Dr Mathew Kurian, Dr Arulmozhi Varman

CASE
SCENARIO
3

A 60 year old male who had an uneventful cataract surgery, now comes back with complaints of a dark shadow in the temporal visual field :

15 Min

How do I manage dysphotopsia post cataract surgery? Dr Aarti Agrawal

SESSION - 2 (09:45 am - 10:30 am)
Cornea Session

Moderators: Dr Quresh Maskati, Dr R Krishnaprasad

CASE
SCENARIO
1

A 75 year old female with a mature cataract in the right eye with guttae visible on slit lamp examination. Additionally, the specular microscopy of same eye shows CV = 62 and CD = 1400:

10 Min

How do I determine whether to proceed with cataract surgery or to opt for DSEK/ DMEK before cataract surgery

Dr Rishi Swarup

05 Min

Does Femtosecond Laser Assisted Cataract Surgery provide an additional advantage in such a case?

Dr Naren Shetty

05 Min

CASE
SCENARIO
2

A 54 year old female, underwent penetrating keratoplasty 6 months ago, for macular corneal dystrophy in the right eye. Patient now has an immature senile cataract of nuclear sclerosis grade 3 in the same eye:

10 Min

What is the right time to operate in this case and how will my surgical technique change?

Dr Himanshu Matalia

10 Min

CASE
SCENARIO
3

A 45 year old male who is a known case of keratoconus came for cataract surgery. Is Toric IOL an option?

10 Min

Toric/ Toric multifocal IOLs in Keratoconus and PMD - My point of view

Dr Himanshu Matalia
Vs
Dr Rishi Swarup

Discussion: 15 Minutes

SESSION - 3 (10:30 am - 10:45 am)
Laser based treatment in complex cornea

Moderators: Dr Chitra Ramamurthy,
 Dr Harshul Tak, Dr Suvira Jain

CASE
 SCENARIO

A 56 year old male with history of undergoing LASIK and having irregular astigmatism due to decentred ablation. What are the options for treatment?

15 Min

Topoguided treatment of cornea with a
 disturbed topography

Dr Chitra Ramamurthy



(10: 45 am - 11:00 am)

Management of small pupil during cataract surgery

Dr Chee Soon Phaik

15 Min

SESSION - 4 (11:00 am -01:00 pm)

**Translational Research, Imaging,
 Innovation in Cataract and Refractive surgery**

Moderators: Dr Quresh Maskati, Dr J K Reddy,
 Dr Chandrashekhar Wavikar

Cell to Clinic Translation

Dr Rohit Shetty

Zepto Capsulotomy - Getting a perfect rhexis from hand to machine

Dr Rishi Swarup

Artificial Intelligence, Corneal Biomechanics and
 Mathematical modelling

Dr Abhijit Sinha Roy

Comparing Newer Topographers

Dr Luci Kaweri

Posterior Corneal Astigmatism and its applications

Dr Chandrashekar Wavikar

New IOL formulae and the future

Dr Mathew Kurian

IOL Innovations

Dr R C Shah

Supracor for presbyopia

Dr Mohita Sharma

Lunch Break : 1:00 pm – 2:00 pm

SESSION - 5 (02:00 pm -02:45 pm)
Presbyopia

Moderators: Dr Arulmozhi Varman,
 Dr Krishnaprasad Kudlu, Dr. Ambarish Darak

CASE
 SCENARIO

1

A 45 year old emmetropic male with dysfunctional lens syndrome:

10 Min

Presbyopic Surgery

Dr. Krishnaprasad K vs Dr Fam Han Bor

My experience of managing a case of presbyopia

Dr. Ambarish Darak

10 Min

CASE
 SCENARIO

2

A 52 year old female with -3 D of myopia, wants to be free of glasses:

20 Min

Options for management

Dr. Somshekar N

10 Min

Devils advocate in multifocal IOL

Dr. Ronald Krueger vs Dr Arulmozhi Varman

10 Min

SESSION - 6 (02:45 pm -03:15 pm)
Uvea

Moderators: Dr MS Ravindra, Dr Krishnaprasad Kudlu

CASE
SCENARIO

A 62 year old male, had an uneventful cataract surgery, presents 1 month later with a visual acuity of 3/60. Hypopyon with 4+ cells and a fibrin membrane over the IOL are seen on slit lamp with a hazy view of the retina:

30 Min

Intravitreal antibiotics or pars plana vitrectomy?
Does EVS still hold true?

Dr Padmamalini M

10 Min

How do I go back and ensure my OT is safe?
Pre-operative measures to minimize endophthalmitis ?

Dr Ramesh Dorairajan

10 Min

Ideal OT and sterilization of instruments

Dr M S Ravindra


10 Min

Tea Break : 3:15 pm – 3:30 pm

YOU Session : Video based learning (03:00 pm - 05:30 pm)

Mentors: Dr Ronald Krueger, Dr Chee Soon Phaik, Dr Fam Han Bor

Moderators: Dr Suvira Jain, Dr Venkatesh, Dr M S Ravindra
Dr Sharon D' Souza



Step by Step Surgical Video Presentations by Fellows/Residents Young Ophthalmologists

Small Pupil Management | Intumescent Mature Cataract | Double Rhexis |
Hard Brown Cataract | Management of Zonular Dialysis | Cataract in High Myopic |
Small and Deep Sockets | Use of Lens Scaffold | Secondary IOL Implantation |
MSICS in Complex Cataract | DM detachment: Air bubble between DM & Dua's layer

*For videos ; 2 Min video followed by 5 Min discussion

International Faculty



Dr. Fam Han Bor

Tan Tock Seng Hospital
Singapore



Dr Chee Soon Phaik

Singapore National Eye Centre
Singapore



Dr. Ronald A. Krueger

Cleveland Clinic
USA

National Faculty

Dr Aarti Agrawal

Dr Abhijit Sinha Roy

Dr Adrian Braganza

Dr Ambarish Darak

Dr Arulmozhi Varman

Dr Chandrashekhar Wavikar

Dr Chitra Ramamurthy

Dr Deepthi Meda

Dr Harsha Rao

Dr Harshul Tak

Dr Hemamalini M S

Dr Himanshu Matalia

Dr J K Reddy

Dr Jyoti Matalia

Dr K Bhujang Shetty

Dr Keya Barman

Dr Krishnaprasad Kudlu

Dr Luci Kaweri

Dr Mathew Kurian

Dr Mohita Sharma

Dr M S Ravindra

Dr Mukesh Paryani

Dr Naren Shetty

Dr Padmamalini M

Dr Praveen Murthy

Dr Quresh Maskati

Dr Ramesh Dorairajan

Dr R C Shah

Dr Rishi Swarup

Dr R Krishnaprasad

Dr Rohit Shetty

Dr R. Venkatesh

Dr Samaresh Srivastava

Dr Sathi Devi

Dr Sharon D'Souza

Dr Somshekar N

Dr Suvira Jain

Dr Vaishali Vasavada

Dr Varun Kharbanda

Dr Y L Rajashekhar



YOU Faculty

Dr Ashima Bajaj

Dr Chaithra Aroor

Dr Kanchan Sainani

Dr Nikhil Kandurwar

Dr Pallak Kusumgar

Dr Pooja Khamar

Dr Poojita V K

Dr Roshan T

Dr Sanket Bhatnagar

Dr Tejal S J

Dr Tushar Grover

Dr Urvija Choudhary

Dr. Vaitheeswaran L G



Before May 10th: 1500/-, After May 10th & Spot Registration : Rs 3000/-

For Transport Logistics & Registration Contact:

Conference Secretariat - Ms. Chitra Seshadri: +91 9449036370

E-Mail: conferences@narayananeethralaya.com; Visit: www.narayananeethralaya.org